






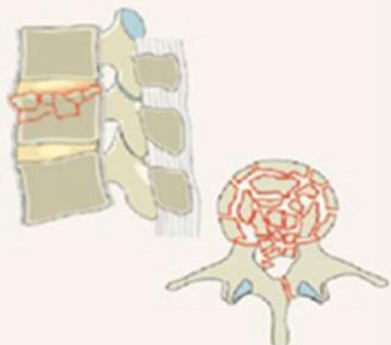


## Indications for MRI Spine

Type A. Compression Injuries	Type B. Distraction Injuries	Type C. Translation Injuries
<p><b>A0. Minor, nonstructural fractures</b></p> 	<p><b>B1. Transosseous tension band disruption / Chance fracture</b></p> 	<p><b>C. Displacement / Dislocation</b></p> 
<p><b>A1. Wedge-compression</b></p> 	<p><b>B2. Posterior tension band disruption</b></p> 	<p><b>B3. Hyperextension</b></p> 
<p><b>A2. Split</b></p> 	<p><b>A3. Incomplete burst</b></p> 	<p><b>A4. Complete burst</b></p> 